11th Batch NEU OSPE

1. The posterior inferior cerebellar artery (PICA) arises from which of the main artery marked as A, B, C and D?

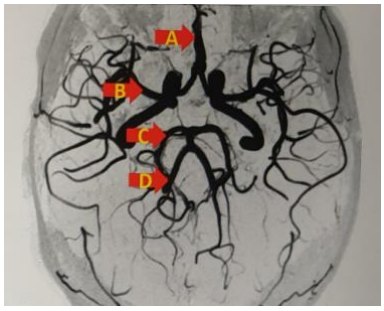

Ans: D (vertebral artery)

2. After gaining consciousness, stroke patient was examined which reveals spastic muscle paralysis in his left upper and lower limb. Mark the area affected on the provided CT scan.

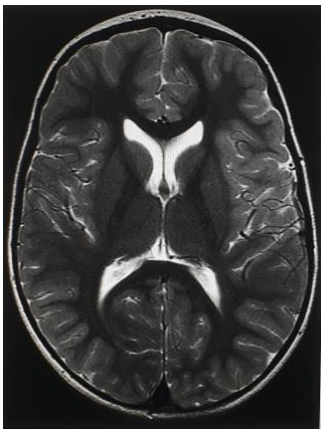

Ans: Right internal capsule (Posterior limb or Genu)

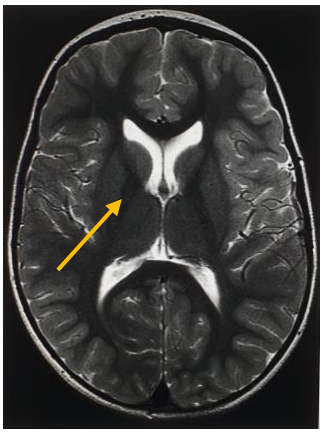

3. A 30-year-old patient, who had recovered from tuberculous meningitis, came to the clinic with severe headache, nausea and vomiting. His MRI reveals hydrocephalus. Which of the structures labelled as A, B, C, and D will be affected in this case to cause hydrocephalus?

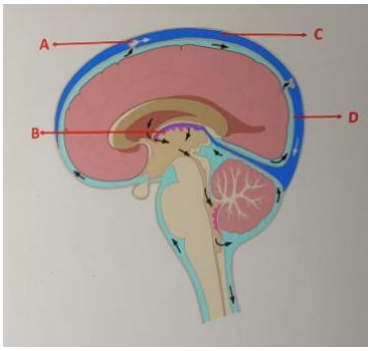

Ans: A (arachnoid granulation)

4. On sensory examination of a patient, there is loss of pain and temperature sensation in his left lower limb. Which one of the labelled tracts in the provided spinal cord section transmits pain and temperature?

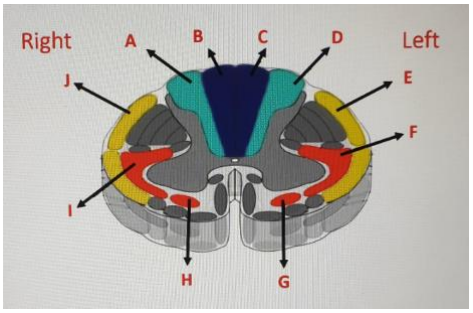

Ans: I (lateral spinothalamic)

5. After a stroke, patient visited speech therapy clinic with a major impairment of language comprehension. Although speech retains natural-sounding rhythm and normal syntax, it is meaningless.
   a. Which one of the labelled cortical areas is affected in this case?
   b. Name the artery involved in this case.

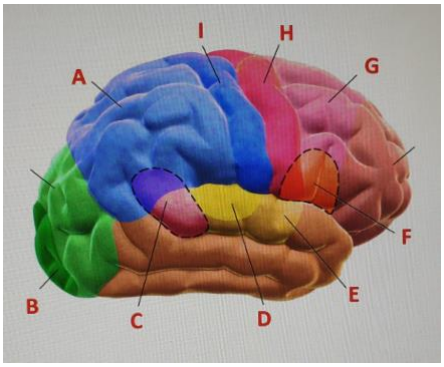

Ans:

a. C (Wernicke's area)

b. Inferior division of Middle cerebral artery

6. Which one of the labelled cells A, B, C, D is responsible for secondary motor function of the body?

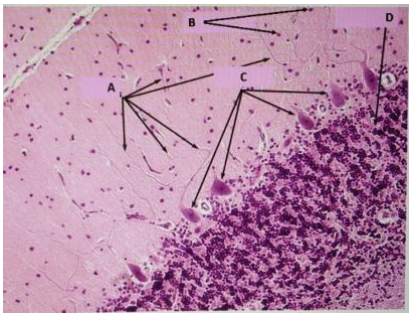

Ans: C (purkinje neurons)

7. A 60-year-old man walked into your clinic with stooped posture and rigid facial expressions. He complains of difficulty in walking for a couple of months and resting tremors. He also mentions that there is difficulty in initiating and performing new movements. On examination, his limbs showed rigidity on passive movement. There is no loss of muscle power and deep tendon reflexes are normal. Which of the marked areas as 1, 2, 3, 4 & 5 in the provided section is affected in this case?

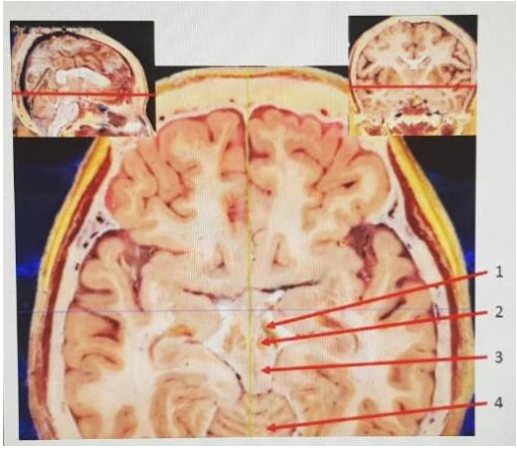

Ans: 1 (substantia nigra)

8. A 45-year-old patient presented with a history of difficulty in swallowing. On examination, there is also loss of taste sensation in posterior 1/3 of the tongue. Which one of the labelled nerves A, B, C D is affected in this case?

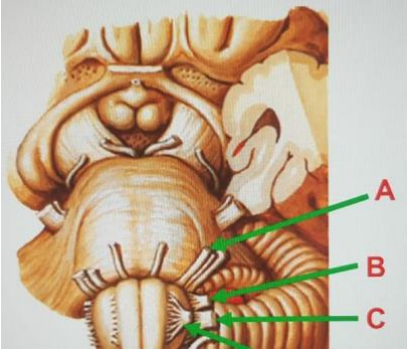

Ans: B (glossopharyngeal)

9. A 65-year-old female presented with weakness of right arm, leg and lower half of her face. Babinski sign was present. Examination also shows ptosis of the left eyelid. When the neurologist lifted her eyelid, the pupil was dilated, and the eye was turned down and out
   a. Based on the signs and symptoms above, which of the sections marked as A, B, C D, E, F shows the correct lesion in the attached image?
   b. Name the artery involved in this case?

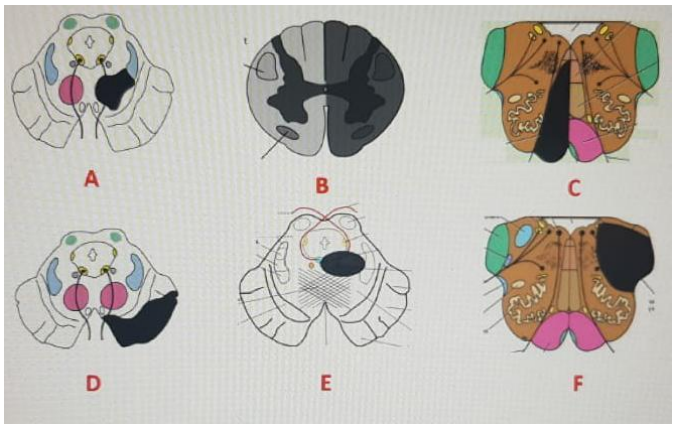

Ans:

a. D (midbrain)
b. Superior cerebellar artery

10. A 44-year-old lady with a 5-year history of lumbar back pain presented to the emergency department, with a severe sharp back pain now radiating into both her buttocks. She also complained of urinary incontinence. On examination, motor strength of her left leg was decreased to 3/5. A digital rectal examination revealed a loss of sensation in the perianal area with reduced anal tone. Which of the marked areas A,B,C and D will be affected in this case?

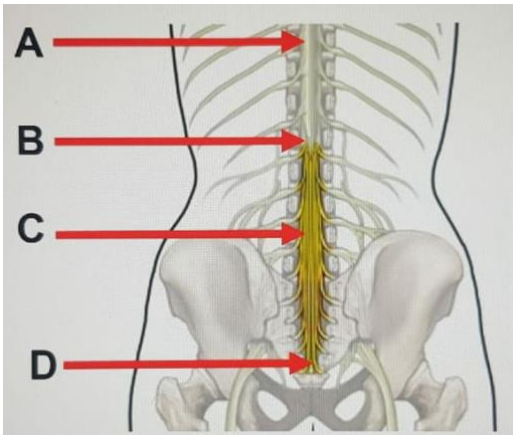

Ans: C (Cauda Equina)

11. Identify the structures marked as A and B.

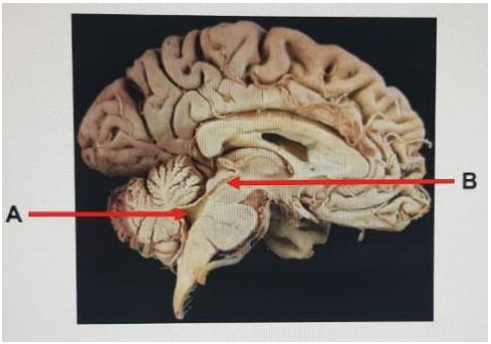

Ans:

a. Fourth ventricle
b. Aqueduct of Sylvius

12. A 45-year-old hypertensive patient presented with sudden freezing painful sensations in her left arm. In addition, she also complains of weakness and numbness down the whole of her left side. When examined locally she was weak and numb on the left side with chorea of the left arm. Which structure marked as A, B, C, D is affected in this case?

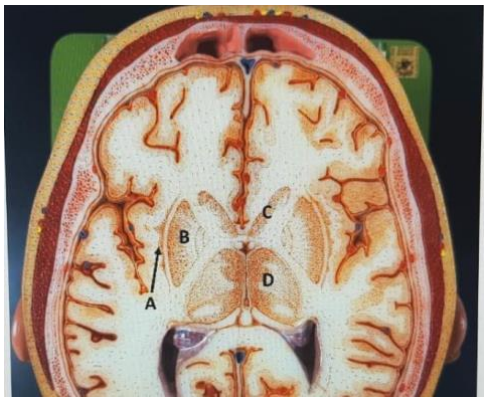

Ans: D (Thalamus)

13. Identify the structure marked as 3 and 4

Ans: 1: Basilar Artery, 2: Pons, 3: Trigeminal Nerve (?), 4: Cerebellum (Dentate Nucleus?)

14. Which of the following biochemical/cytological profile in CSF analysis would you expect if the microscopic examination with India ink shown in the attached image?

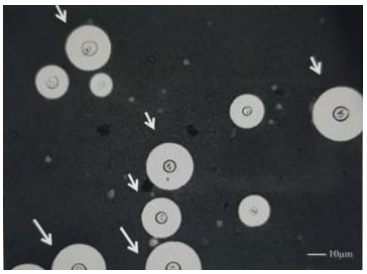

A. Opening pressure moderately increase, WBC increased 50% lymph, glucose slightly decreased
B. Opening pressure elevated (450mm HO), protein decreased, Gram stain negative
C. Gram stain positive, glucose significantly decreased, protein normal
D. Increased WBC predominantly neutrophils, glucose increased, opening pressure normal
E. Glucose normal, WBC increased, 70% lymph, protein slightly elevated

Ans: A

15. Which of the organisms marked as 1,2,3,4 is related to neonatal meningitis and is associated with the consumption of raw dairy products during pregnancy?

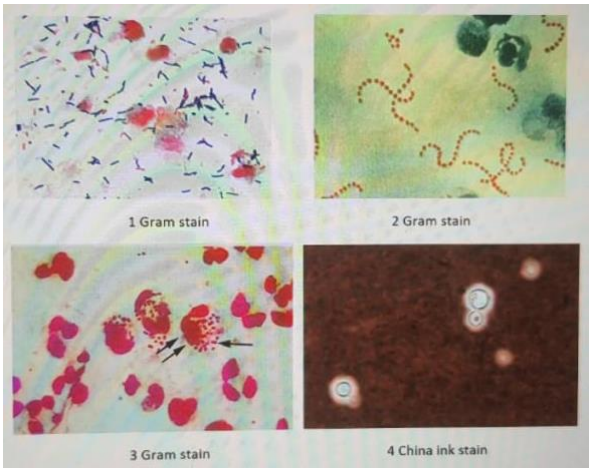

Ans: A (Gm+ Rods = *L. monocytogenes*)

16. A medical student recorded the EEG waves in a relaxed, calm and quite laboratory setting while he was awake with his eyes closed. While recording he was asked to open his eyes, which of the EEG wave A,B,C,D tracing frequency will diminish?

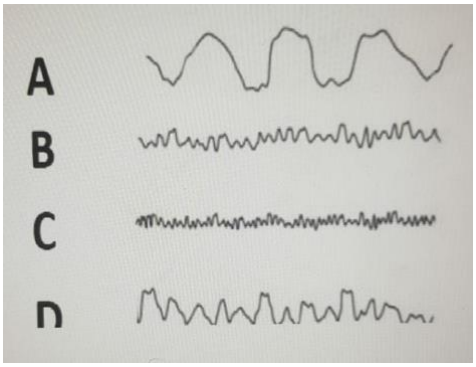

Ans: B (α waves)

17. What will be the most probable motor deficit if the vessels marked with red circle in the attached picture are occluded?
    Mark the illustration below which more accurately shows motor deficit. (purple area indicates motor loss)

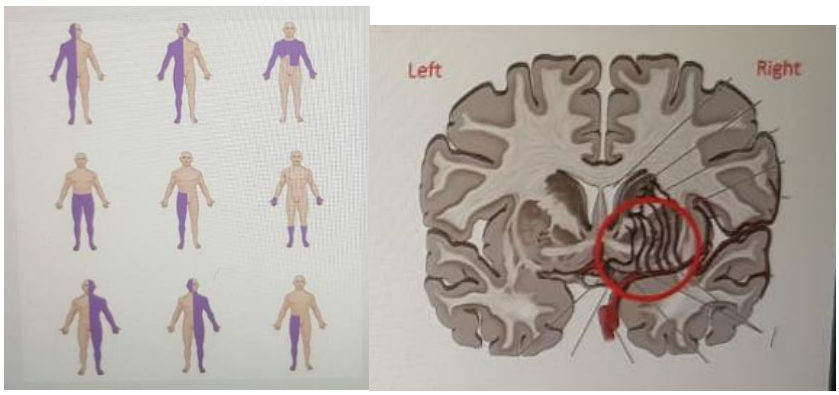

Ans: Lenticulostriate branch of middle cerebral artery (supplies posterior limb of the internal capsule).



18. Which group of neurons marked as A, B, C is involved in case of poliomyelitis?

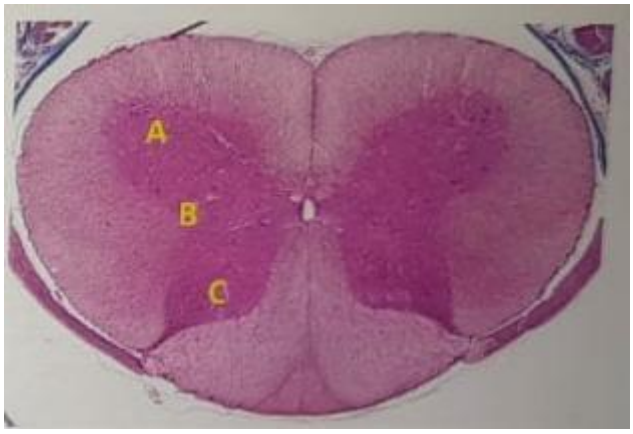

Ans: A (Anterior horn cells)

19. a. Which of the labelled parts in the provided section transmits visual fibers?
    b. Name the artery supplying the area marked as C (Be specific)

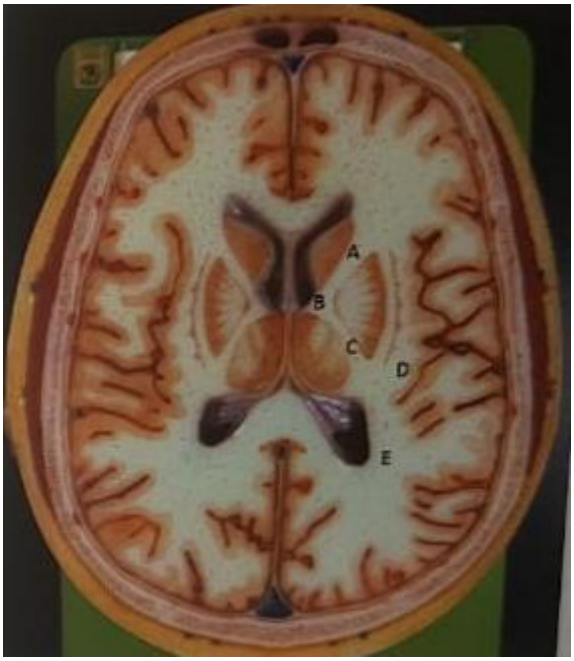

Ans:

a. E (Retrolenticular part of the internal capsule in the Occipital lobe)

b. Lenticulostriate branch of middle cerebral artery (supplies posterior limb of the internal capsule).

20. The nerve conduction velocity of the median nerve is determined as shown in the diagram. The nerve is stimulated at S in the elbow and the response recorded at R in the wrist, 28 cm away. If the latency is 4 milliseconds calculate the conduction velocity of the nerve in meters per second (m/sec).

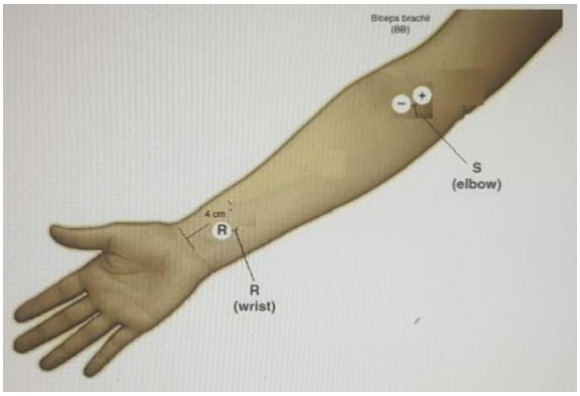

a. 7 m/sec
b. 14 m/sec
c. 28 m/sec
d. 70 m/sec
e. 140 m/sec

Ans: D, $\frac{28\ cm \div 100}{4\ millisec \div 1000} = \frac{0.28m}{0.004sec} = 70\ m/sec$

$$v = \frac{d}{t}$$

v = speed
d = distance travelled
t = time taken